

# Pygmy Goat Medal Test Study Guide

## GOLD LEVEL

### STUDY Bronze & Silver Study Guides

**Stomach:** Goats have one stomach made up of 4 chambers: rumen, reticulum, omasum, and abomasum. Each of the four chambers has a particular purpose and function.

The **rumen** is the largest chamber of the ruminant stomach (1-2 gallon capacity) and has no digestive enzymes. It is a large fermentation vat populated by microorganisms which change nondigestible cellulose into proteins which can be used by the body. Roughage is worked on by the microorganisms, regurgitated and rechewed (as a cud), then swallowed and the process is repeated. Eventually the processed food passes on through the reticulum to the omasum in a condition ready to be digested by normal body enzymes. Methane is produced continuously as a by-product of bacterial action, so odiferous belches are a sign of health rumen. Anything which harms the rumen microorganisms can effectively halt the digestive process.

The **reticulum** lies in front of and below the rumen, near the liver. Its lining is honeycombed and it serves as a catch chamber for heavy articles in the feed. In cattle, magnets are often placed in the reticulum to catch and hold nails, pieces of wire and other hardware the animal might swallow. Since goats are more fastidious in their eating habits, magnets are not necessary. The reticulum from cattle is sold in the market as tripe.

The **omasum** is divided by long folds of tissue which help decrease the size of food particles coming from the rumen and which also help remove excess fluid.

The **abomasum** is the true stomach and is the only compartment which produces digestive enzymes. It acts on food prepared by the rumen just like the simple stomach acts on food entering from the mouth. It is the area of primary digestion of all grain and milk. Grain and milk do not require the efforts of rumen microorganisms.

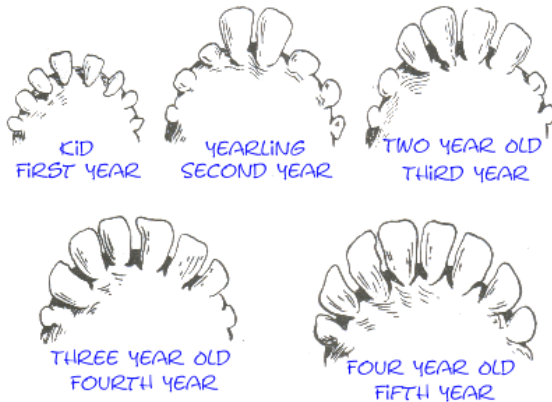
**Shots:** When giving CD&T we are vaccinating goats against two diseases. The C and D component vaccinates goats against a disease called enterotoxemia, caused by the bacteria *Clostridium perfringens type C & D*. The T is to vaccinate against *tetanus*. BO-SE is a *selenium and vitamin E* supplement, not a vaccination.

**Yearly Testing:** Reputable breeders and responsible goat owners will try and protect their goats and breeding programs from infiltration of disease, mainly Caprine Arthritis and Encephalitis (*CAE*), *Johnes* (pronounced Yo-knees), and Caseous Lymphoma (*CL*). They all can be done with the same blood sample.

- **Caprine Arthritis and Encephalitis (CAE):** This disease has two forms: the arthritis (visible) and the encephalitis (internal). They both wreak havoc on dairy herds in the world. This disease causes painful arthritic joints, mastitis, decreased milk production. Once a goat has this disease they can never rid themselves of it. The disease will be passed from mother to kid through the milk.

- **Johnes Disease:** pronounced (Yo-knees) This disease shows up as rapid weight loss and diarrhea and may stay dormant for many years. Once an animal has this disease there is no cure and it can spread very quickly in the herd. (<http://www.johnes.org/goats/diagnosis.html>)
- **Caseous Lymphoma (CL):** This disease causes abscesses around the lymph glands most often around the jawline which burst open and drain. Once this disease is in your soil it is there forever.

**Teeth:** Goats have 32 teeth- 8 front lower teeth (*incisors*) and a "Dental Pad" (Gums) on the front top, these are used for biting off leaves and small branches. In the back on both top and bottom are the pre-molars and molars (24 in all) they use for chewing.



The baby teeth in the front are lost 2 at a time- starting at approximately 1 1/2 yr old. They lose the front middle 2 teeth, the following year they lose the second set of 2- and so on.

This is an easy way to "age" a goat- until it becomes 5 yrs old which by then you must use the wearing and condition of the remaining teeth to attempt to age the goat.

## ANATOMY:

**Know the front and rear leg bones & joints of a pygmy goat.**

